

Cutaneous fistula of ribs and lymph nodes hydatidosis

Issoufou Ibrahim¹, Ouadnoui Yassine¹² and Smahi Mohamed¹²

Abstract

Hydatidosis is a cosmopolitan anthroponozoonose due to development of the larval form of a taenia canids called *Echinococcus granulosus*. Cutaneous fistula of chest wall hydatid cysts remains rare. The double localisation on lymph nodes and ribs has not yet been described. We present the case of 58 years old man with cutaneous fistula of ribs and lymph nodes hydatidosis mimicking a tumor lesion. A complete resection with safe margins was performed. We propose to review the pathogenic and therapeutic aspects of this rare entity.

Keywords: Echinococcosis; Lymph Nodes; Cutaneous Fistula; Thoracotomy.

1 Introduction

Hydatidosis is a cosmopolitan anthroponozoonosis due to development of the larval form of a canids taenia called *Echinococcus granulosus*. It is endemic in areas of the Mediterranean basin. It is characterized by clinic and topographic polymorphism and a large frequency of complication. Cutaneous fistula of hydatid cysts of the chest wall remains rare. The association of lymph nodes and ribs location has not yet been described. Through observation, we report the first case of its cutaneous fistula. We propose to review the pathogenic and therapeutic aspects of this rare entity.

¹ Thoracic surgery department, Teaching Hospital Hassan II, Morocco

² University Sidi Mohamed Ben Adellah, Faculty of Medicine and Pharmacy, Morocco

2 Case presentation

Mr Z.B, 58 years old, with any past medical history consulted in our service for an anterior chest wall cutaneous fistula since 6 months. The clinical examination showed a patient in good condition with a chronic soft swelling of the right supero-external dual of the breast area, coursing for 10 years, and cutaneous fistula leaving out the pus. The palpation of the ipsilateral axillary region (right) found two lymph nodes of hard consistency. Chest x-ray showed a right basal opacity with irregular limits. The bacteriological analysis of the pus has highlighted a *Staphylococcus meti S* sensitive to oxacillin which was prescribed. Chest CT (figure 1) showed an osteolytic process of the 3rd and 4rd rib with a fluid bone collection and a cystic image between major and minor pectoralis muscles. The suspicion of tumoral process imposed to complete the radiological assessment with brain, abdominal and pelvic CT which has not showed any lesion. A resection of the two lymph nodes was performed. The histological analysis (figure 2) revealed a cystic process with fibrous wall containing some scolex and hydatid membrane. The lymphoid tissue was replaced by a polymorphous inflammatory infiltrate surrounding the walls of the cyst. The diagnosis of cutaneous fistula of lymph nodes and ribs hydatidosis was retained. An anterolateral thoracotomy following the 4th intercostal space was performed resecting the cutaneous fistula. The pectoralis major muscle was laden with hydatid vesicles. The avulsion of this muscle showed a multiple hydatid vesicles in the thickness of the anterior part of the 2nd, 3rd and 4rd ribs. A flatting of the bone abscess associated with resection of the anterior parts of these ribs were carried out (figure 3). The exploration also found an axillary hydatid cyst which was resected completely without breaking its hull. An antihelminthic treatment was prescribed for 6 months and the patient was discharged on the fourth postoperative day.

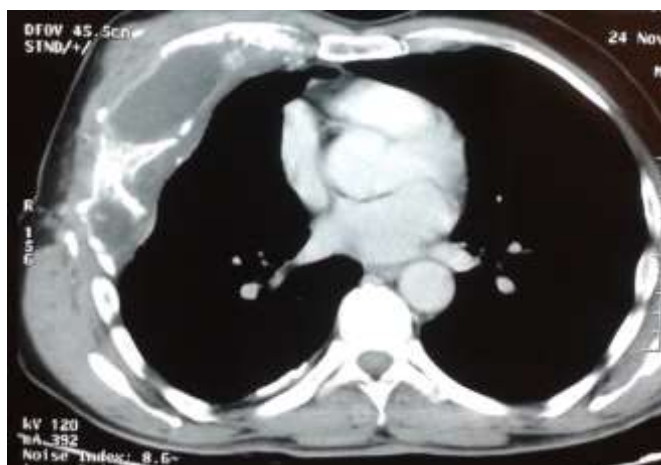


Figure 1: Chest CT showing an osteolytic process of the 3rd and 4rd rib with a fluid bone collection.

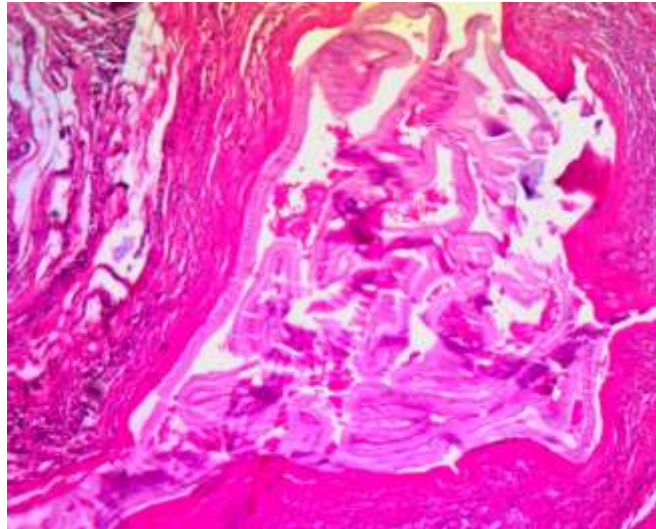


Figure 2: Cystic process with fibrous wall contained some scolex and hydatid membrane.

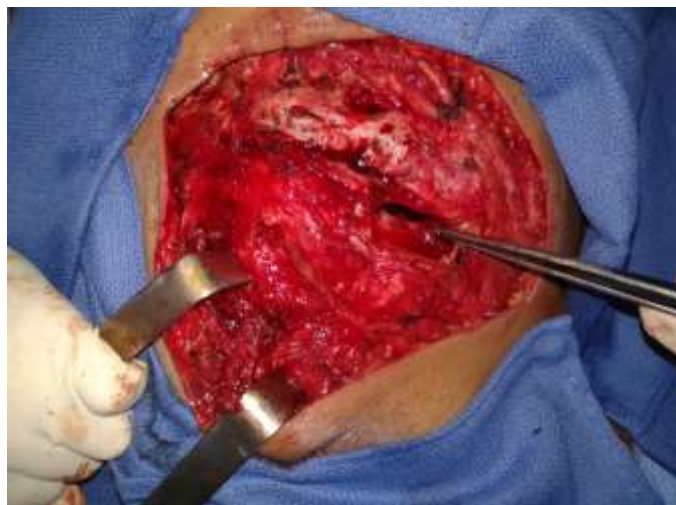

Figure 3: operative view showing the cavity of the hydatid bone abscess (patient in supine position, his head at the top)

3 Discussion

The location of the hydatid cyst in the chest wall is rare even in endemic countries. It is of 0.09 to 2% of the chest locations [1]. About 50% of bone hydatid disease is located in the spine, then the pelvic with 21% [2]. But liver (75%) and lungs (15%) are the most common sites [3]. The dissemination to the chest wall is through haematogenous way. The ingested egg reaches the portal circulation

through intestinal wall and joins the liver and then the lung. When those filters are exceeded, the egg penetrates the systemic circulation and thus all organs can be achieved including the bone. In the ribs, hydatidosis develops by vesicle multiplication in the thickness of the bones because of rigidity of the bone tissue. As against, hydatid lymph node localization is rarely reported in the literature. Through the intestine lymphatic, the hydatid egg regains lymphatic circulation and thus penetrates the lymph nodes. The symptomatology can remain latent for many years [4], which explains the lengthy evolution in our patient. A little tumefaction is the first clinical signs then increasing volume. The infection of this collection could be the cause of fistula [1]. Ribs tuberculosis has sometimes the same clinical history leading to a diagnosis problem especially in hydatid and tuberculosis endemic countries. Thoracic CT and MRI are the gold standard. The presence of multiple cyst images is very evocative in endemic country [5]. But when radiological images do not show any vesicle structures or hydatid membranes and when axillary lymph nodes are found, a tumor etiology must be eliminated. Indeed, chondrosarcoma, which is the most common primary malignancy chest wall tumor, can show these kind of radiological images as well as osteosarcoma which can causes osteolysis and cortical rupture [6]. Therefore getting histological diagnosis is necessary. MRI was not performed in our patient because it is indicated in posterior ribs locations with suspicion of vertebral extension [5]. The cure of bone hydatidosis is surgery. Surgical resection of ribs and soft-tissue with negative margins is the primary treatment [4]. Medical one is additionnal. The dose per day is about 10 to 15 mg/kg. The length of the post-operative anti-parasitic treatment is linked to the presence of a complication, the intra-operative findings, the type of the operation (complete resection or not) and the presence of viable *Echinococcus granulosus* in the cyst [7, 8]. It also depends on hepatic tolerance to albendazole and the patterns of the institution. Should lymphadenectomy been performed systematically? Being the lymph node hydatidosis description very fewer in literature [9], a standardised approach would be difficult to adopt. Buttenschoen K et al. suggested a lymphadenectomy in the case of hepatic cysts of *Echinococcus multilocularis* with lymph nodes extension [9]. This position seems being the best because of two reasons:

- First, surgery would ensure a radical resection of the nodes.
- Secondly, medical treatment which could be an alternative therapy is curative only in half of cases [10].

4 Conclusion

Cutaneous fistula of ribs and lymph nodes hydatidosis is a rare entity. Thoracic CT and MRI are the gold standard in radiological assessment. Its treatment is based on surgical resection with negative margins. The lymphadenectomy should be performed for a complete treatment. The albendazole therapy must be complementary to surgery to avoid recurrences.

Conflict of interest: none

Acknowledgements. The assistance of the radiology unit in acquiring images is gratefully acknowledged.

References

- [1] I. Zendah , S. Ben Saad, H. Daghfous, Kyste hydatique de la paroi thoracique mimant une métastase de cancer colique, *Revue de Pneumologie clinique*, (65), (2009), 357-360.
- [2] J. Ben Amar, H. Zaibi, B. Dhahri, Recurrent iliac hydatidosis: A case report, *International Journal of Surgery Case Reports*, (7), (2015), 79–81.
- [3] A.T. Sayit, P.H. Gunbey, K. Aslan, A case of disseminated hydatid disease by surgery involving multiple organs, *Asian Pacific journal of tropical disease*, 4(Suppl 2), (2014), S660-S663.
- [4] N. Karaoglanoglu, M. Gorguner, A. Eroglu, Hydatid Disease of Rib, *The Annals of thoracic surgery*, (71), (2001), 372-375.
- [5] Y. Ouadnouni, M. Bouchikh, A. Achir, Hydatidose costale, *Revue de Maladie Respiratoire*, (28), (2011), 306-311.
- [6] Brouchet L., Ballouhey Q., Brouchet A., Giron J., Berjaud J., Renaud C., Benouaich V., Dahan M. Tumeurs primitives de la paroi thoracique. *EMC (Elsevier Masson SAS, Paris), Pneumologie*, 6-002-G-69, 2010.
- [7] M. Stamatakos, C. Sargedí, C. Stefanaki, Anthelmintic treatment: an adjuvant therapeutic strategy against *Echinococcus granulosus*, *Parasitology International*, (58), (2009), 115–135.
- [8] C. Dziri, K. Haouet, A. Fingerhut, Management of cystic echinococcosis complications and dissemination: where is the evidence?, *World Journal of Surgery*, (33), (2009), 1266–1339.
- [9] K. Buttenschoen, P. Kern, S. Stefan Reuter, Hepatic infestation of *Echinococcus multilocularis* with extension to regional lymph nodes, *Langenbeck's Archives of Surgery*, (394), (2009), 699-704.
- [10] Riquet M et Souilamas R. Kyste hydatique pulmonaire. Indications thérapeutiques. *Encycl Méd Chir (Editions Scientifiques et Médicales Elsevier SAS, Paris, tous droits réservés), Pneumologie*, 6-003-M-10, 2000, 6 p.