

Female Pelvic Prolapse: Considerations on Mesh Surgery and our Experience with Prolift Mesh in 84 Women with Complicated Pelvic Prolapses

**Edoardo Tartaglia¹, Giampaolo Delicato¹, Giulio Baffigo¹
and Stefano Signore¹**

Abstract

Introduction: Pelvic organ prolapse (POP) is a common condition in women because of the weakening of the pelvic support system during lifetime. The surgical approach of POP was changed by using different mesh or graft materials. During the last 5 years we treated 84 women with complicated POP by using a prolene mesh. We analysed the results.

Materials and Methods: Eighty-four women, studied by urodynamics and cystography, underwent surgery for the correction of III-IV stage POP using a prolene mesh. In 55 we positioned an anterior Prolift, in 29 a total prolift; in 44 with stress urinary incontinence a sling under the urethra was also positioned. The follow-up took place after 12 months.

Results: No major complications occurred. In 5 (6%) cases a mild perineal hematoma occurred; in 5 (6%) just coxofemoral pain. Five (5.7%) mesh erosions and three (3.6%) II degree cystocele were recorded. All patients are continent.

Conclusions: Even if a validated and generally accepted measure of subjective prolapse symptoms is required, the surgical repair of the POP by using Prolift

¹ S.Eugenio Hospital-Department of Urology, Italy

mesh appears to be an effective procedure with encouraging outcomes, also in complicated cases.

Keywords: pelvic organ prolapse, meshes and grafts, vaginal repair, prolift

1 Introduction

Pelvic organ prolapse (POP) is a very common condition, particularly among older women. It is estimated that half of women who have children will experience some form of prolapse in later life. The actual number of women affected by prolapse however is unknown because many women do not seek help from their doctor. It is also estimated that one in 11 women requires surgery for pelvic organ prolapse in their lifetime, most of them over 40 [1].

Reasons for this remarkable social problem are simple. The network of muscles, ligaments and connective tissue in and around a woman's vagina acts as a complex support structure that holds pelvic organs in place. When this support system weakens or collapses, the pelvic organs shift their position and fall down into the vagina (like the uterus) or push up against the walls of the vagina (like the urinary bladder and bowel). The most common cause of pelvic floor muscle weakness is strain during a vaginal birth, especially if the baby was large or if the labour was long and difficult [2,3]. Lower levels of oestrogens can also make the ligaments and muscles of the pelvis weaker and less elastic: this is what often happens in post-menopausal women. Sometimes pelvic prolapse can also occur after a hysterectomy; if the uterus is removed, other organs, such as the bladder, may drop. Although in many cases it is not possible to diagnose a precise cause, occasionally prolapses may simply be associated with obesity, chronic coughing or chronic constipation.

Usually pelvic organs prolapses can be divided according to the side of vagina they affect; that is the front vaginal wall, posterior vaginal wall and top of the vagina. So we distinguish between cystocele and urethrocele in the first group; enterocele and rectocele in the second; and uterine prolapse (grade 1, 2 and 3 according to its severity) and vaginal vault prolapse in the third.

All of the above conditions of prolapse usually get worse over time and require surgery to correct them. It is obvious that pelvic prolapses cannot be considered a life threatening condition. However they can cause a great deal of discomfort and distress (pain during sexual intercourse, urinary incontinence, difficulty in bowel voiding, etc) and as such it is always necessary to resolve the problem.

Current treatment options for anterior and posterior vaginal wall prolapse include pelvic floor muscle training (PFMT), use of pessaries (mechanical devices such as rings or shelves), and surgery including anterior or posterior colporrhaphy and site-specific defect repair. Nowadays surgery can be augmented with implantation of mesh or graft materials, with the aim of reducing the risk of failure [1,4,5].

The new interpretation of pelvic disfunctions, as already mentioned, is based on the knowledge of fascial and ligamentous weakness. The aim of surgery therefore should be to restore the normal anatomy of the pelvic floor, meaning the normal support and function of all ligaments and muscles. In order to obtain this result, many different kinds of meshes have been developed and used. The last generation of these meshes seems to indicate promising results without a high complications rate [4,6].

During the course of the last 5 years we used one of the meshes of the last generation, called Prolift mesh (a prolene mesh) and we treated 84 women with complicated pelvic prolapses and analysed the results.

2 Preliminary Notes

Between November 2006 and February 2011, 84 women underwent surgery for the correction of vaginal prolapses using the Gynecare Prolift™ prolene mesh. The median age of the women was 61 (41-76); all patients presented a third or four stage prolapse using POP Q criteria and were studied by urodynamics and cystography in 44 cases there was also a stress urinary incontinence (SUI).

In 55 cases women presented a vesical prolapse (one in Fig.1) and we performed the positioning of an anterior Prolift.

In 10 women who had a cystocele associated to hysterocele, a total prolift with colposuspension was positioned; in one of these ten cases a hysterectomy was necessary.

In the other 19 women there was a vaginal vault prolapse associated to rectocele. In these patients their more complicated prolapse was also treated by a total prolift. Characteristics of the patients are showed in Table 1 (1a+1b) and in Graphic 1 (1a+1b).

All patients underwent an antibiotic therapy before surgery for 48 hours (ciprofloxacin 400 mg + metronidazole 1000-2000 mg i.v./die).

This surgery was always performed with a general anesthesia and, of course, with the patient in a gynaecological position.

After vaginal incision and dissection of vaginal wall fascia (Fig.2), incisions for mesh/graft introducer points are made in the skin (Fig.3) . The surgeon palpates and controls the introducer movement within the pelvic cavity using landmarks (anatomical) as it perforates. Mesh/graft is connected to the perforating end of the introducer. The mesh is stabilised by the mesh tapes that are pulled through the introducer points.

The prolene mesh is fixed to sacrospinal ligament. This mesh is then positioned on the vaginal apex or the cervico-vaginal fascia, and on the anterior space (vesico-vaginal space) and/or on the posterior space (recto-vaginal space) as showed in Fig.4.

Forty-four patients with SUI were also treated by positioning a sling under the median urethra.

3 Main Results

All patients underwent a general anesthesia with a median operating time of 45 minutes (33-86).

The median blood loss was 200cc. No vascular or visceral complications occurred. All patients had a vesical catheter for 48 hours and a vaginal medication for 24 hour. All patients left the hospital within 3 days after surgery. In 5 (6%) cases a mild perineal hematoma occurred and in 5 (6%) cases coxofemoral pain needed antiinflammatory drugs.

The follow-up took place and urogynaecological evaluation was performed after 1, 3, 6, 12, 20 months from surgery. The results are showed in Table 2.

Six erosions of the mesh were recorded (7.1%), but no mesh was removed. Two erosions occurred in the middle of vaginal wall and were treated with estrogens while four were on the lateral wall and were treated with conservative therapy, and no surgical treatment.

These outcomes substantiate the medical literature about the early erosion in the first six months [7,8,9,10].

No prolapse recurrence was observed in 50 women, as opposed to three who exhibited second degree cystocele (3.6%).

We also recorded only three patients (3.6%) with dyspareunia; this outcome seems to deny one of the most cited complications for the use of mesh. In reality our results should consider that some women, due to their age or to recent pelvic surgery, are not sexually active. However we made the best possible estimates by using two outcomes: persistent dyspareunia in women having dyspareunia at baseline (efficacy), and de novo dyspareunia in women without dyspareunia at baseline (safety). All patients are continent.

3.1 Advantages

Pelvic Organs Prolapse affects woman's quality of life by its local physical effects (pressure, bulging, heaviness or discomfort) or its effect on urinary, bowel or sexual function. Urinary symptoms include both incontinence and retention (incomplete emptying); bowel symptoms may include constipation or faecal incontinence and sexual symptoms include difficulty or the inability to have intercourse due to pain (dyspareunia) or embarrassment.

Pelvic reconstructive surgery, even if often performed easily by many surgeons, requires not only an extensive specialized training and proficiency, but also a proven dedication to understand the women needs, expectations, and goals. For this reason, the surgery of pelvic organs prolapse did not have encouraging results for a long time with a recurrence rate of about 60%, mostly with a vaginal access.

Throughout the last decade the modern materials and devices have improved the treatment of urinary incontinence and the treatment of pelvic prolapses. According to recent researches the fascial and ligamentous weaknesses responsible for pelvic disfunctions, seem to be better corrected by meshes of the last generation.

There are numerous types of mesh and grafts available, which differ in their level of absorptibility by the host tissue, type of material, structure, and physical properties such as tensile strength and elasticity. There are no existing classification systems for mesh and grafts. Therefore, in theory, absorbable mesh or graft materials are less likely to cause problems with erosion, but may have higher failure rates because they are eventually absorbed. In contrast, non-absorbable mesh, which is always synthetic, is thought to be more likely to cause erosion, though with lower failure rates.

Non-absorbable synthetic mesh had significant and statistically lower objective failure rates (9%) than absorbable synthetic mesh (23%) and absorbable biological graft (18%).

Literature has demonstrated that the surgical removal rate due to erosion (complete or partial) is 2.9% for absorbable synthetic mesh, 2.6% for absorbable biological graft, and 6.6% for non-absorbable synthetic mesh [5]. The results for mesh erosion are similar in women having posterior repair and anterior and/or posterior repair. According to the global outcomes, mesh or graft repair is theoretically suitable for any degree of symptomatic anterior and/or posterior vaginal wall prolapse. It may be more suitable for women with recurrent prolapse, who have a higher risk of failure compared with women undergoing their first repair, or for women with congenital connective tissue disorders (such as Ehlers-Danlos or Marfan's) [5]. Older women may also have a higher risk of failure.

We performed this surgery in the last 5 years just in women with complicated prolapses and positive outcomes in terms of relapse of prolapses, recurrent urinary infections and dyspareunia were obtained.

In our experience therefore the prolapse repair by Prolift-prolene mesh appears to be a very effective procedure, always respecting the general consensus in contraindications for the use of all meshes and grafts [11] (Table 3). Women with a history of previous pelvic radiation, with a severe urogenital atrophy, with the

presence of active pelvic or vaginal infection and patients currently on systemic steroids are not candidates for this surgery.

4 Labels of figures and tables

Table 1a: Patients Characteristics

Patients (total)	84
Average age (yo)	61
Cystocele III – IV degree (%)	100
Prolift + TOT	44
Prolift	40

Table 1b: Patients Characteristics

Patients (total)	84
Anterior Prolift	55
Total Prolift	29
○ <i>Total Prolift + Culposuspension (Cystocele + Hysterocele)</i>	9
○ <i>Total Prolift + Culposuspension + Hysterectomy (Cystocele + Hysterocele)</i>	1
○ <i>Total Prolift (Vaginal Vault Prolapse)</i>	19

Table 2: Complications and side effects

Item	Figures	%
Patients	84	100
Mild perineal hematoma	5	6
Erosions	6	7.1
Coxifemoral pain	5	6
Second degree cystocele	3	3.6
Dyspareunia	3	3.6

Table 3: Contraindications to the use of mesh

History of previous pelvic irradiation
Severe urogenital atrophy
Immunosuppressed patients
Patients currently on systemic steroids
Host factors including: <ol style="list-style-type: none"> 1. Poorly controlled diabetes 2. Morbid obesity 3. Heavy smokers

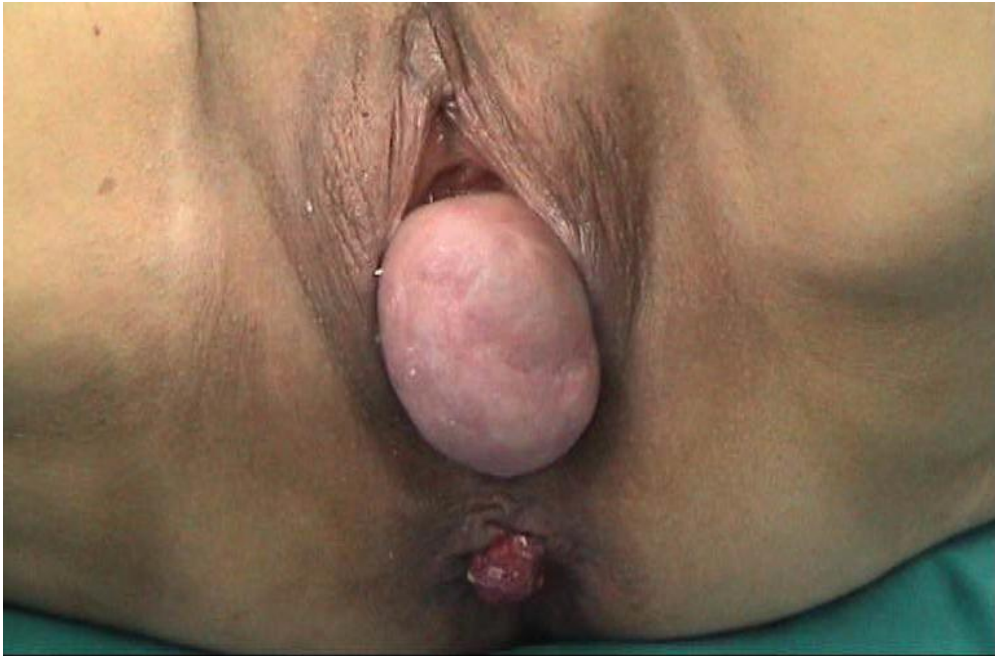

Figure 1: a vesical prolapse

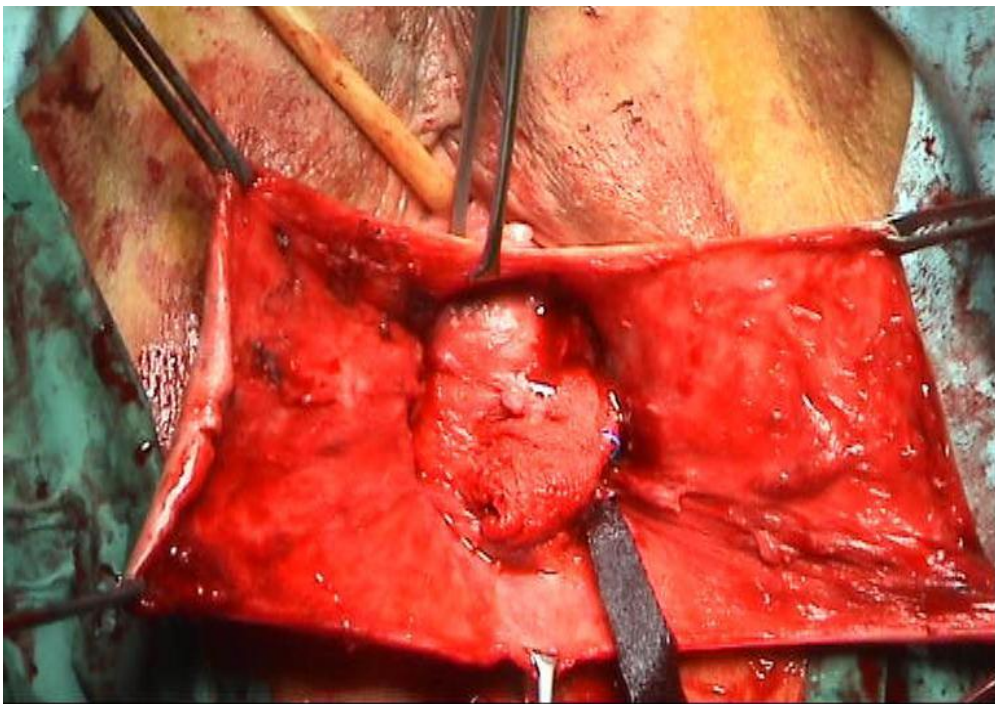


Figure 2: the vaginal incision and the dissection of vaginal wall fascia

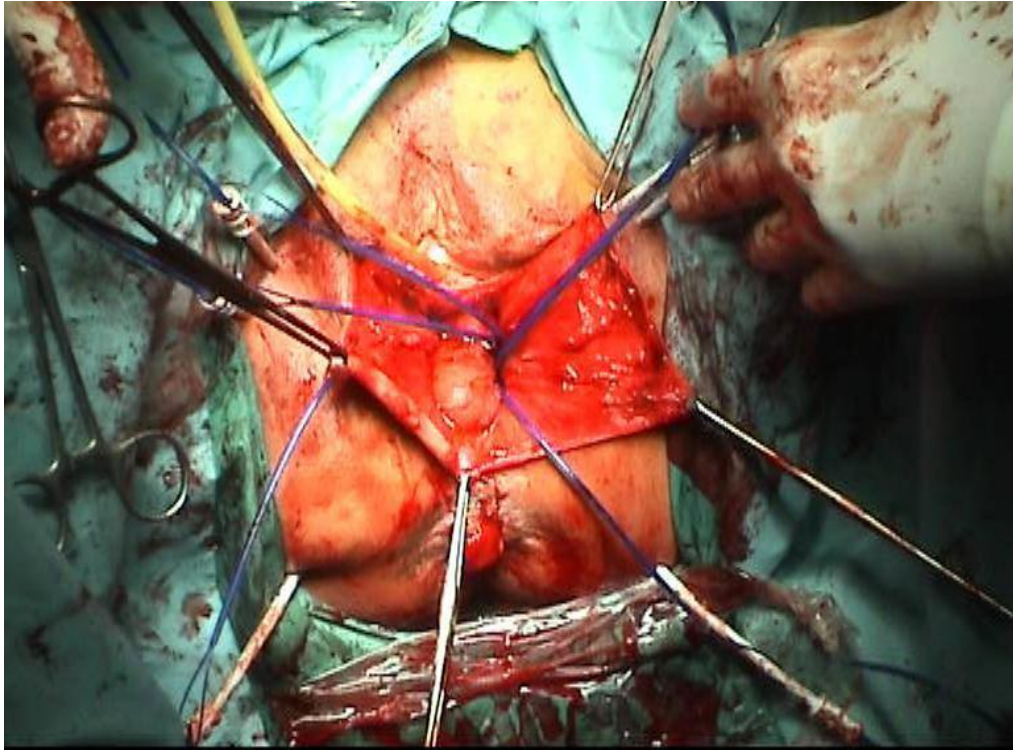


Figure 3: the positioning of mesh introducer after skin incisions

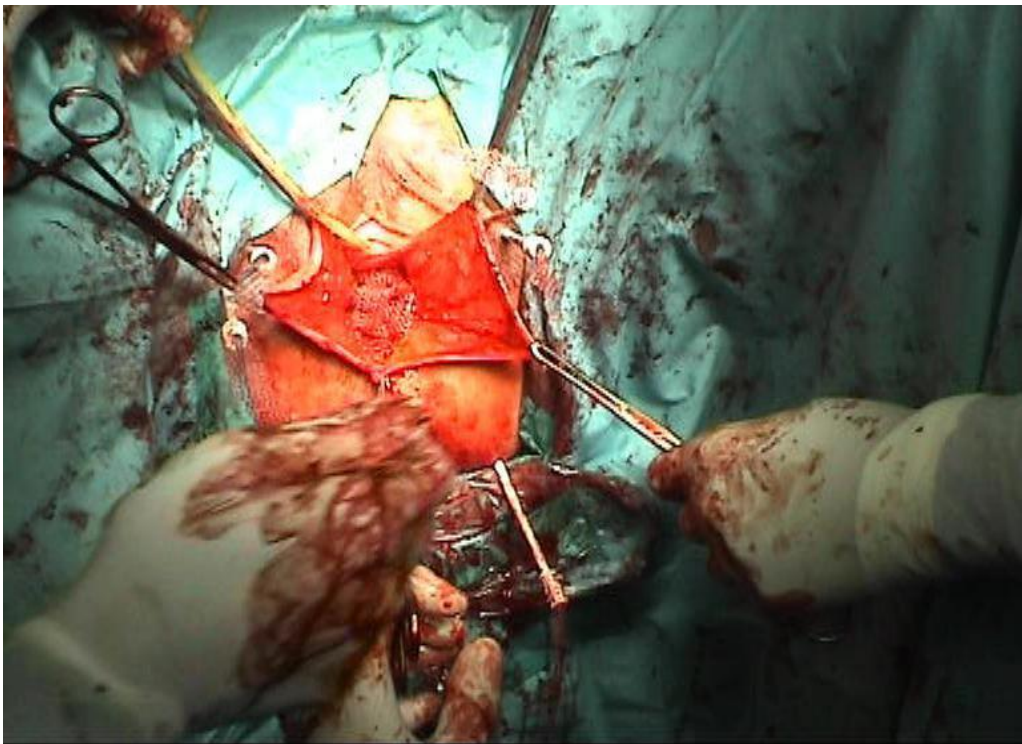


Figure 4: mesh positioned on the anterior space (vesico-vaginal space)

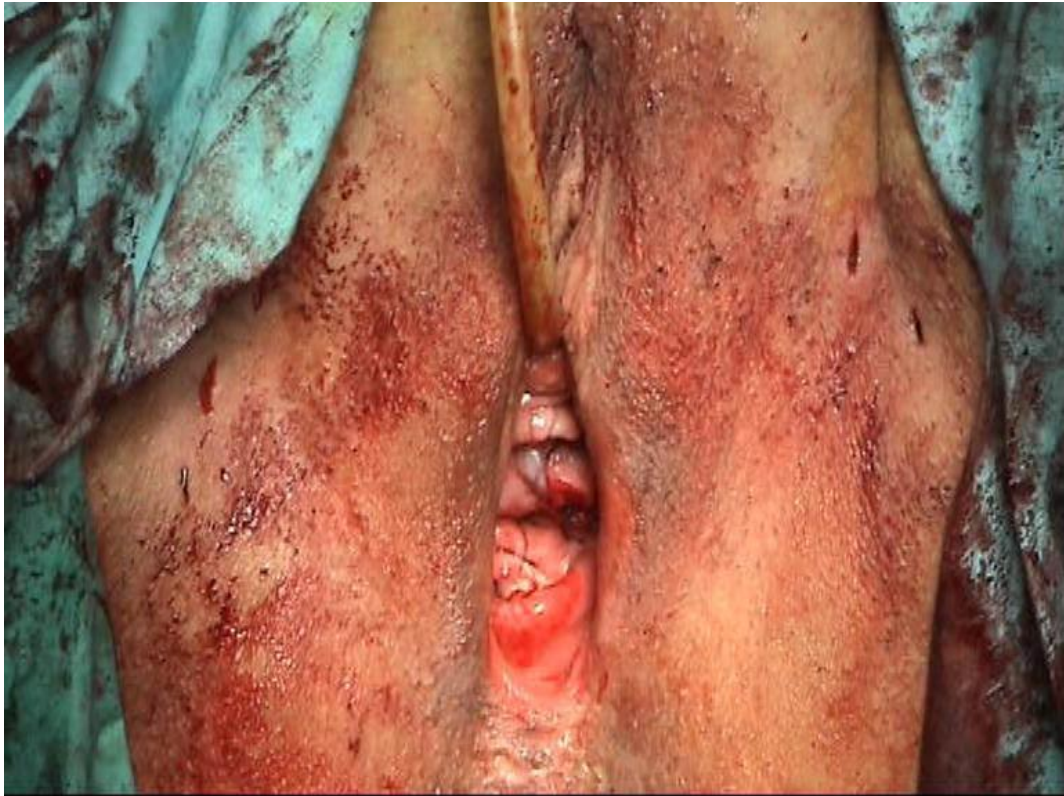

Figure 5: the final encouraging outcome of a complicated prolapse

5 Conclusion

Nowadays there is still no validated and generally accepted measure of subjective prolapse symptoms, although several have been published [12,13]. At the same time better knowledge is required regarding indications for mesh and graft usage, specific biological and chemical properties of the available types of mesh or graft, short- and long- term risks and benefits of graft usage, as well as the optimal implantation technique [11]. Surgeons need therefore to have the expertise to manage any complications associated with the use of mesh or graft.

Despite all of this, and despite the need for further future research about long term-efficacy and safety, the surgical repair of the vaginal prolapses by using Prolift mesh appears to be an extremely effective procedure with encouraging outcomes (Fig.5), even in complicated cases.

Further studies could perhaps take into account how financing may affect the future usage of these materials; not all surgeons will have access to mesh/graft.

References

- [1] Caquant F, Collinet P, Debodinance P, Berrocal J, Garbin O, Rosenthal C, Clave H, Villet R, Jacquetin B, Cosson M: Safety of Trans Vaginal Mesh procedure: retrospective study of 684 patients. *J Obstet Gynaecol Res.* 2008 Aug;34(4):449-56.
- [2] DeLancey JO, Kearney R, Chou Q, Speights S, Binno S: The appearance of levator ani muscle abnormalities in magnetic resonance images after vaginal delivery. *Obstet Gynecol* 2003;101:46-53
- [3] Snooks SJ, Swash M, Mathers SE, Henry MM. Effect of vaginal delivery on the pelvic floor: a 5 year follow-up. *Br J Surg* 1990;77:1358-60.
- [4] Carlsen SN, Pshak T, Flynn BJ, Aurora CO: Total pelvic floor reconstruction utilizing Prolift, a polypropylene mesh reinforced pelvic floor repair and vaginal vault suspension. Abstract Video Session/ Female Urology – 2008 AUA Annual Meeting, Orlando FL (USA).
- [5] Iia X, Glazener C, Mowatt G, McLennan G, Fraser C, Burr J: Systematic review of the efficacy and safety of using mesh or grafts in surgery for anterior and/or posterior vaginal wall prolapse. Review Body for Interventional Procedures October 2007.
- [6] Birch C, Fynes MM: The role of synthetic and biological prostheses in reconstructive pelvic floor surgery. *Curr Opin Obstet Gynecol.* 2002 Oct;14(5):527-35.
- [7] De Tayrac R, Deffieux X, Gervaise A, Chauveaud-Lambling A, Fernandez H: Long-term anatomical and functional assessment of trans-vaginal cystocele repair using a tension-free polypropylene mesh. *Int Urogynecol J Pelvic Floor Dysfunct* 2006;17:483-8.
- [8] Flood CG, Drutz HP, Waja L: Anterior colporrhaphy reinforced with Marlex mesh for the treatment of cystoceles. *Int Urogynecol J Pelvic Floor Dysfunct* 1998;9:200-4.
- [9] Deffieux X, De Tayrac R, Huel C, Bottero J, Gervaise A, Bonnet K et al: Vaginal mesh erosion after transvaginal repair of cystocele using Gynemesh or Gynemesh-Soft in 138 women: a comparative study. *Int Urogynecol J Pelvic Floor Dysfunct* 2007;18:73-9.
- [10] Julian TM: The efficacy of Marlex mesh in the repair of severe, recurrent vaginal prolapse of the anterior midvaginal wall. *Am J Obstet Gynecol* 1996;175:1472-5.
- [11] Davila GW, Drutz H, Deprest J: Clinical implications of the biology of grafts: Conclusions of the 2005 IUGA Grafts Roundtable. *Int Urogynecol J Pelvic Floor Dysfunct* 2006;17:S51-S55.
- [12] Price N, Jackson SR, Avery K, Brookes ST, Abrams P: Development and psychometric evaluation of the ICIQ Vaginal Symptoms Questionnaire: the ICIQ-VS. *BJOG* 2006;113:700-12.

- [13] Barber MD, Kuchibhatla MN, Pieper CF, Bump RC: Psychometric evaluation of 2 comprehensive condition-specific quality of life instruments for women with pelvic floor disorders. *Am J Obstet Gynecol* 2001;185:1388-95.