

Bladder Cancer Presenting with Wide Spread Cutaneous Metastasis: A Case Report

**Muzzammil Abdullahi¹, Bashir Yunusa¹, Sharfuddeen Abbas Mashi¹,
Sani Ali Aji¹ and Sani Usman Alhassan¹**

Abstract

Cutaneous metastasis from bladder cancer is rare; the presence of such metastasis is suggestive of an advanced staged bladder cancer with potential rapid progression and fatal outcome. Bladder cancer metastasis to the skin present in various forms which can be localized nodules or wide spread. Treatment by systemic chemotherapy with gemcitabine and cisplatin or MVAC regimen has been shown to improve patient's outcome.

Keywords: Bladder cancer, skin, metastasis, prognosis

1 Introduction

Bladder cancer is the ninth most common cancer throughout the world and is considerably more common in developed than developing countries [1]. In the United States of America (USA), bladder cancer is the fourth most common cancer in males and twelfth in the females [2]. In Egypt, Sudan, part of Middle East and other areas where schistosomiasis is endemic, bladder cancer has been reported to be the commonest cancer among males [3].

In developed countries, over 90% of bladder cancer cases are transitional cell

¹ Bayero University, kano, Nigeria

carcinoma (TCC), with squamous cell carcinoma (SCC), adenocarcinoma, and other rare types comprising the remaining 10% [1]. In Africa and other developing countries where schistosomiasis is endemic, SCC may account for up to 75% of all bladder cancers [2]. An unusually high prevalence of bladder cancer has been reported from parts of Northern Nigeria accounting for 19.8% and 6.4% of all cancers in Sokoto and Kano respectively. Of these, 65.1% was SCC, and 27.3% was TCC in Sokoto while in Kano SCC accounted for 53% and TCC was 35%. Others were adenocarcinomas and rare histologic forms [3, 4]. Similarly, another study in Kano, Northern Nigeria reported that most patients presented with advanced bladder cancer (locally advanced and distant metastatic) out of which about 55% had radical cystectomy while others had palliative chemotherapy [5]. The exact aetiology of bladder cancer is unknown. Several risk factors have been linked to development of bladder cancer such as chronic cystitis, schistosomiasis, cigarette smoking, synthetic nitrogen fertilizers, organophosphate-based pesticides, aromatic amines, pelvic irradiation, cyclophosphamide, human papilloma virus and genetic predisposition [2]. Bladder cancer most commonly metastasizes to lymph nodes, liver, lung and bone. Metastases to other sites such as the skin, spleen, heart, kidney, pancreas, brain, and stomach are uncommon. The incidence of cutaneous spread from primary urologic malignancies is reported to be 1.3%. Urinary bladder alone accounts for 0.84% of cutaneous metastasis. Cutaneous metastases from bladder cancer have been shown to have poor prognosis [6]. We present a patient who presented with rapidly spreading cutaneous metastatic nodules from bladder cancer.

2 Case Presentation

A 47-year-old Man who first presented to us with complaints of haematuria for 3 months, passage of necrotic tissues in urine and weight loss for 1 month. Haematuria was painless, initially terminal and later became total. There were both irritative and obstructive lower urinary tract symptoms. He had a history of childhood terminal haematuria which was poorly treated, however, there was no history of cigarette smoking or exposure to industrial chemicals. On physical examination, he was wasted, pale, anicteric, no facial puffiness or pedal oedema. Pulse and blood pressure were normal. Abdominal examination revealed a full abdomen with a barely palpable suprapubic mass. There was no hepatomegaly, kidneys were not ballotable and no ascites. On bimanual there was a mass at the region of the bladder which was hard nodular and non-mobile. Prostate was mildly enlarged with benign features. He had the following investigations done: urine analysis, urinary microscopy, culture and sensitivity, urine cytology, full blood count, serum urea, electrolytes and creatinine, abdominal ultrasound scan (USS), and urethrocystoscopy and biopsy.

The urine cytology showed malignant cells, abdominal USS showed a tumour in the bladder occupying most of the bladder cavity with bilateral

hydronephrosis. There were no liver deposits, no ascites. Urethroscopy showed a bladder tumour occupying most of the base and the lateral walls, ureteric orifices could not be visualized, the urethra, prostate and bladder neck were grossly normal. Histology confirmed urothelial carcinoma. Other investigations done were essentially normal. He was counselled for radical cystectomy and urinary diversion. He however defaulted (said to be trying traditional medications). He represented three months later with uraemic symptoms (from obstructive nephropathy) and few skin nodules on the trunk. The nodules became wide spread within a week as shown in Fig. (1&2).

He was admitted and commenced on haemodialysis to optimize him for a possible urinary diversion and chemotherapy. During this period one of the subcutaneous nodules was taken for histology which came out to be subcutaneous metastatic transitional carcinoma (Fig 3a and 3b). He however deteriorated and died.

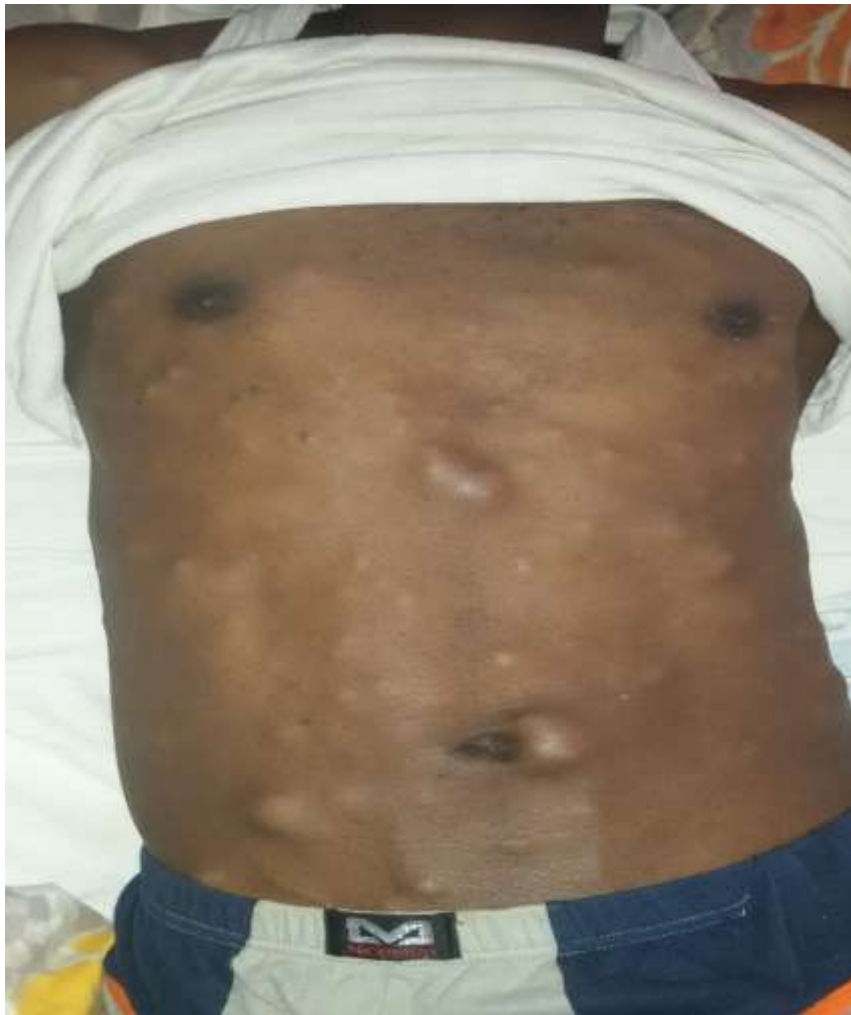

Figure 1 : Cutaneous and Subcutaneous nodules on the anterior abdominal wall

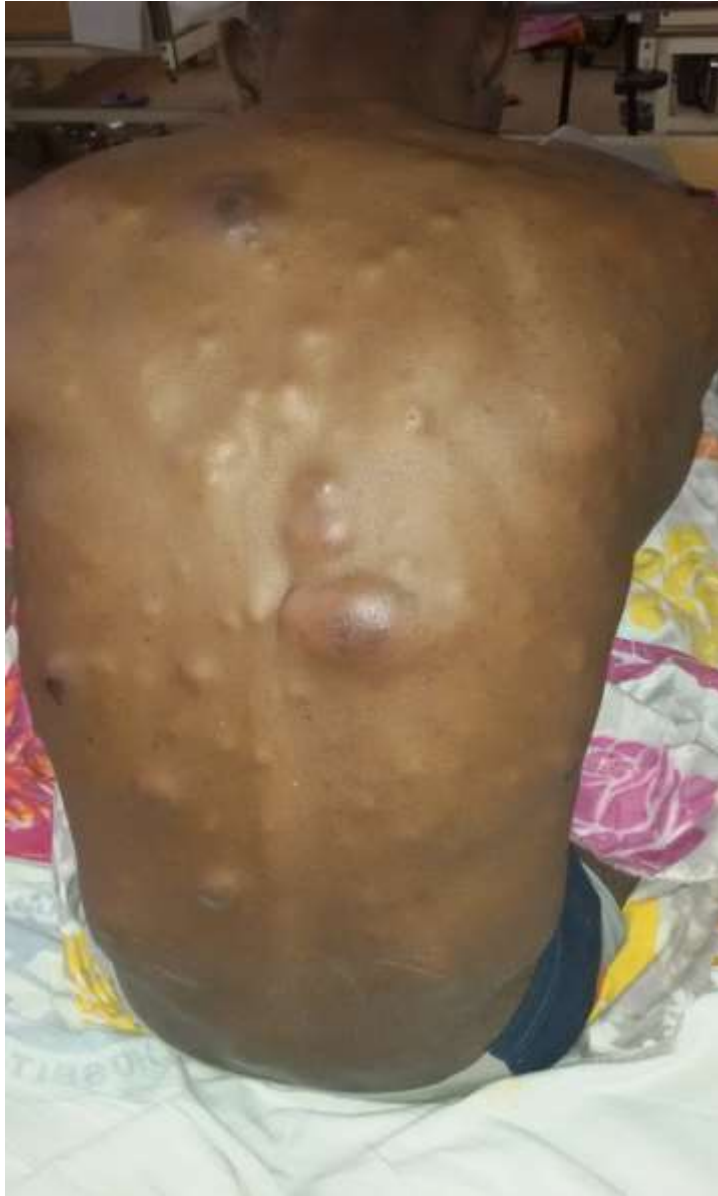

Figure 2: Cutaneous and Subcutaneous nodules on the posterior abdominal wall

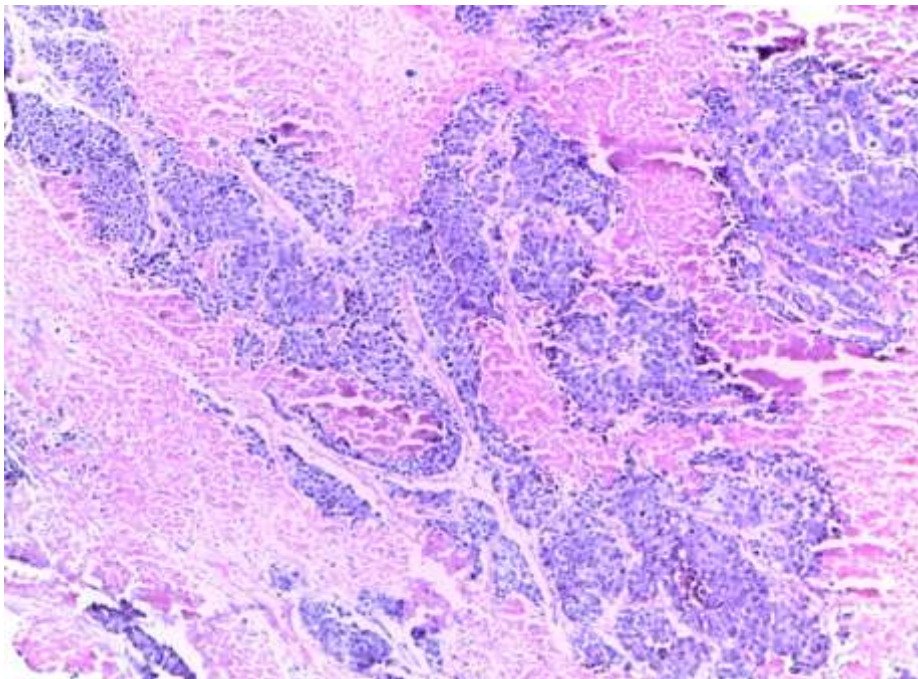


Figure 3a: Invasive Urothelial Carcinoma showing infiltrating urothelial nests of malignant epithelia cells within a desmoplastic lamina propria... (H&E) X20

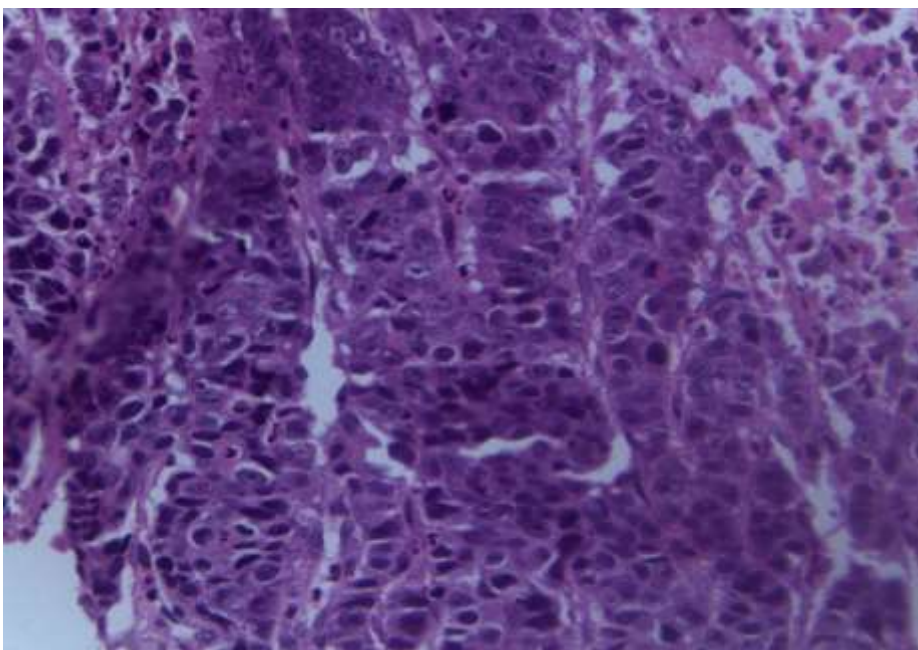


Figure 3b: Invasive Urothelial Carcinoma showing infiltrating urothelial nests of malignant epithelia cells within a desmoplastic lamina propria... (H&E) X20

3 Discussion

The liver, lung, and bone are the most common sites for metastases from genitourinary malignancies. Cutaneous and subcutaneous metastases from urologic malignancies are uncommon and rarely do they occur at the time of the diagnosis, indeed they are mostly associated with advanced cancer with poor prognosis, since most of the patients die within few months from their appearance [7]. Cutaneous metastases are more frequently associated with other solid tumours such as epidermoid lung carcinoma, breast and lung adenocarcinoma [7].

Metastatic infiltration of bladder cancer to the skin and subcutaneous tissue can be by direct infiltration, haematogenous or lymphatic spread or by iatrogenic implantation of cancer cells during procedures. An iatrogenic implantation is considered as the main cause of skin involvement in majority of patients with transitional cell carcinoma. The iatrogenic procedures, such as cystectomy, suprapubic cystostomy, pyelotomy and laparoscopy are the most common causes of seedling of transitional cell carcinoma outside the urinary tract [8]. In our patient the spread is likely to be haematogenous or lymphatic as the only procedure he had was urethrocystoscopy.

Clinically cutaneous metastases from carcinoma of the bladder shows various aspects mimicking different skin conditions such as furuncles, sebaceous cysts, inflammatory plaque, sclerodermoid, pseudo-aneurysm, herpes zoster, oedematous, erysipelas or cellulites-like lesions. Cutaneous metastases may morphologically resemble the primary tumour. These lesions can have a nodular, inflammatory, or fibrotic appearance and can be solitary or multiple. However, they are often poorly differentiated, thus immunohistochemical investigation is often required to determine the primary origin [7, 9].

In the index patient the metastases are mainly nodules with some having sebaceous cyst like apex and are multiple as shown in Fig 1&2.

Treatment options are often limited and palliative due to the patients' disease stage, resulting in poor prognosis. The treatment of choice for metastatic bladder cancer is chemotherapy, which however is rarely curative. Currently, the combination of gemcitabine and cisplatin and the MVAC regimen (methotrexate, vinblastine, doxorubicin, and cisplatin) are established treatments with reported tumour remission rates of up to 70%. Survival, however, does not exceed 14 months [8-10].

The role of surgery in the metastatic bladder cancer has not been fully investigated. Surgical resection can be performed in cases with persistent or recurrent disease that is resectable.

4 Conclusion

Cutaneous metastases from bladder cancer are rare and suggest advanced staged disease with poor prognosis. Early diagnosis and aggressive effort at correcting

renal impairment and onset of systemic chemotherapy are necessary options to improve the outcome of the patient.

References

- [1] SA Fedewa, AS Soliman, K Ismail et al. Incidence analyses of bladder cancer in the Nile delta region of Egypt. *Cancer Epidemiol.* 2009; 33: 176–181.
- [2] GD Steinberg, BF Schwartz. Bladder Cancer. <http://emedicine.medscape.com/article/438262-overview>.
- [3] IA Mungadi, SA Malami. Urinary bladder cancer and Schistosomiasis in North-Western Nigeria. *WAJM* 2007; 26: 226-229.
- [4] O Ochicha, S Alhassan, AZ Mohammed et al. Bladder cancer in Kano- A histopathological review. *WAJM*.2003;22: 202-204.
- [5] SU Alhassan, A Abdullahi, AA Sheshe et al. Radical cystectomy for locally advanced carcinoma of bladder in Kano, Nigeria. *African journal of urology*.2007; 13:112-118.
- [6] MAS Narayana, R Patnayak, N Rukmangadha et al. Cutaneous metastasis of transitional cell carcinoma of the urinary bladder: Cytological aspect. *J Cytol.* 2014; 31: 50–52.
- [7] A Campanati, V Brisigotti, D Dusi. Et al. Bladder urothelial cell carcinoma metastatic to the skin. *ISSN* 2013; 1: 22–25. Published online 2013 April 5.
- [8] NS Salemis, C Gakis, A Zografidis, Gourgiotis S Et al. Cutaneous metastasis of transitional cell bladder carcinoma: A rare presentation and literature review. *J Can Res Ther* 2011; 7:217-219.
- [9] CI Chang, I Yen Lee, S Hung-Jen .Unusual presentation of cutaneous metastasis from bladder urothelial carcinoma. *Chin J Cancer Res.* 2013; 25: 362–365.
- [10] S Aliyu, US Bello, BS Mohammed, et al. Squamous Cell Carcinoma of the Bladder Presenting with Ocular and Generalized Skin Metastasis. *International Journal of Science and Research (IJSR) ISSN (Online)*.2012; 3:374-37